

Laser Biomodification of the Bone Bed Surface for Placement of Spiral Dental Implants: a Study Based on Scanning Electron Microscopy

Nikolay Kanazirski¹, Deyan Neychev¹, Ralitsa Raycheva², Nikolay Zahariev^{3,4}

¹ Department of Oral Surgery, Faculty of Dental Medicine, Medical University of Plovdiv, Plovdiv, Bulgaria

² Department of Social Medicine and Public Health, Faculty of Public Health, Medical University of Plovdiv, Plovdiv, Bulgaria

³ Department of Pharmaceutical Sciences, Faculty of Pharmacy, Medical University of Plovdiv, Plovdiv, Bulgaria

⁴ Research Institute at Medical University of Plovdiv, Plovdiv, Bulgaria

Corresponding author: Nikolay Kanazirski, Department of Oral Surgery, Faculty of Dental Medicine, Medical University of Plovdiv, 15A Vassil Aprilov Blvd., 4002 Plovdiv, Bulgaria; Email: nkanazirski@gmail.com

Received: 24 Aug 2023 ♦ **Accepted:** 6 Oct 2023 ♦ **Published:** 31 Dec 2023

Citation: Kanazirski N, Neychev D, Raycheva R, Zahariev N. Laser biomodification of the bone bed surface for placement of spiral dental implants: a study based on scanning electron microscopy. *Folia Med (Plovdiv)* 2023;65(6):993-999. doi: 10.3897/folmed.65.e111609.

Abstract

Introduction: Various rotary and mechanical instruments are used in conventional oral surgery for osteotomies. Despite the implementation of effective cooling systems, it is difficult to prevent thermal damage to the adjacent bone caused by heat generated during the procedure. A smear layer forms on the surface, which can impede the interaction of blood elements with the underlying tissue, resulting in a delayed healing process.

Aim: This study explores the possibility of overcoming these drawbacks by combining conventional methods with a pulsed Er:YAG laser. By examining the osteotomy surfaces using scanning electron microscopy (SEM), we investigated the potential synergistic effects that could benefit conventional implantology.

Materials and methods: Split osteotomies were performed on mandibles of freshly euthanized domestic pigs (*Sus scrofa domestica*). With osteotomy surface examination, the experimental comparison involved two groups: group A - standard technique, and group B - surface ablation using an Er:YAG laser by applying our own method. The samples from both groups were examined using scanning electron microscopy (SEM).

Results: In group A samples, the bone surface was smooth, with an amorphous layer and microcracks all over it. The thickness of this layer ranged from 21.77 μm to 136.2 μm , completely obstructing the Volkmann's and Haversian canals. In group B, the borders were smooth and well defined. The bone structure remained unchanged, with empty intratrabecular spaces, no signs of carbonization, and open canals reaching the surface. The smear layer measured between 3.054 μm and 47.26 μm , with complete absence observed in some places.

Conclusions: The present study provides evidence that ablation of the osteotomy surface using an Er:YAG laser leads to biomodification by eliminating the smear layer without altering the parameters of the bone bed.

Keywords

biomodification, Er:YAG laser, implant site, smear layer, SEM

INTRODUCTION

The development of implantology and the advent of osseointegrated screw implants have created new avenues for efficient, practical, and aesthetically beautiful patient care. However, there is a delay in the implant osseointegration process that takes several months. Factors such as the formation of a smear layer of unmineralized collagen and proteoglycans on the osteotomy site surface, as well as increased temperature leading to carbonization when using rotary instruments, can all impair healing.^[1-3] Some authors have provided evidence that these factors hinder the interaction of blood elements with the underlying bone, leading to delays and problems in the osseointegration process.^[4-6] Laser surgery advancements gives perspectives for improving certain aspects by providing effective bone ablation and decontamination without generating excessive heat that could damage adjacent tissues. This capability is only available with the Er:YAG and Er,Cr:YSGG lasers. The Er:YAG lasers with a wavelength of 2940 nm (in the near-infrared spectrum) are of particular interest. These lasers offer precise beam geometry, short pulse modes with ample irrigation for cooling, and prevent the risk of carbonization and necrosis. Some authors investigate the temperature rise of implant surfaces, soft tissues, and bone during irradiation with diode, CO₂, and Er:YAG lasers. They established that diode and CO₂ lasers increased significantly the temperature of more than 46°C, whereas the temperature in the Er:YAG laser group was less than 30°C. The authors reported a statistically significant difference between diode, CO₂, and Er:YAG lasers in favor of erbium lasers and they concluded that the Er:YAG laser demonstrates the best thermal properties during irradiation of the implant surface.^[7] Consequently, it becomes possible to remove the smear layer, improve the healing process, and facilitate accelerated osseointegration. Tsanova and Tomov^[8] investigated morphological changes with SEM in hard dental tissues after treating them with Er:YAG and various rotary tools. The authors concluded that teeth surfaces prepared with Lite Touch Er:YAG laser (Light Instruments Ltd, Israel) remained smear layer-free and with clearly exposed dentinal tubules orifices. The surfaces were highly retentive.^[8] Yaneva and Karaslavova^[9] studied the root cementum surface of teeth with periodontitis instrumented with an Er:YAG laser using SEM. They reported that surfaces which were instrumented with Er:YAG laser displayed micro-roughness without a smear layer, with exposed collagen fibers and clean cementum matrix.^[9] Despite their potential, the Er:YAG lasers are underutilized in routine clinical practice for a variety of reasons, one of which is a lack of sufficient studies of bone characteristics with various laser modes.^[10,11]

AIM

This study aimed to compare and analyze the morphological characteristics of the bone after conventional osteotomy

with drills, followed by Er:YAG laser ablation of the implant bed walls using the method proposed by us. The examination was conducted using scanning electron microscopy (SEM). We investigated whether a synergistic effect exists that could benefit conventional implantology.

MATERIALS AND METHODS

Experimental split osteotomies were performed on the mandibles of ten domestic pigs (*Sus scrofa domestica*). We used the lower edge of the mandible because the characteristics of the bone are similar to those of the alveolar ridge in an edentulous jaw. The biospecimens were obtained from a regulated slaughterhouse immediately after euthanizing the animals. To make sure the bone kept its viable qualities, the treatment was administered within the first hour. The biospecimens were divided into two groups. In Group A, an osteotomy site was formed using rotary drills following the protocol of the NeO implants (Alpha-Bio Tec) with implantology unit Bien Air Chiropro (Bien-Air Dental SA, Switzerland). In group B, the osteotomy surface formed as in group A was irradiated with an Er:YAG laser (Lite Touch, Light Instruments Ltd, Israel) emitting at a wavelength of 2940 nm. The preset program Granulation Tissue Ablation with the following parameters was used: laser energy 400 mJ; pulse frequency 17 Hz; water spray level 6; power 6.80 W; non-contact mode. A side firing tip 1.3 mm in diameter and 19 mm in length was used. It emits energy at 90° to the longitudinal axis and within a 180° perimeter. Therefore, the treatment was carried out in two quadrants – medial and distal (vestibular and oral). Treatment started from the bottom of the implant bed and continued towards the coronal part, with light rotary movements, first in one, then in the other quadrant for about 2-3 minutes. In this way, the entire cavity surface was treated from the bottom to the coronal part (**Figs 1a, 1b**).

Following the necessary preparations, the mandible specimens were cut around the osteotomies to obtain 1×1×1-cm cubes. The cubes were fixed in 10% formalin. Since the experimental study required cutting the samples in half, after drying them, we split the blocks with a hammer and chisel. Cutting with a separator or another mechanical tool produces a contaminant layer that covers the surface and compromises the examination. To secure the blocks in the microscope chamber for examination, they were previously glued to slides with colorless epoxy resin.

Structural and morphological changes in bone tissue after both implant bed preparation modalities - with drills (group A) and with drills followed by laser irradiation (group B), were investigated using scanning electron microscopy (Prisma E SEM, Thermo Scientific, Waltham, MA, USA). The scanning electron microscope is equipped with a thermal emission SEM column, a CCD camera (**Fig. 2**), and a multi-purpose sample holder for 7 stubs. The samples were examined at an accelerating voltage of 10 kV and several magnifications (65×, 120×, 350×), using a low-vacuum

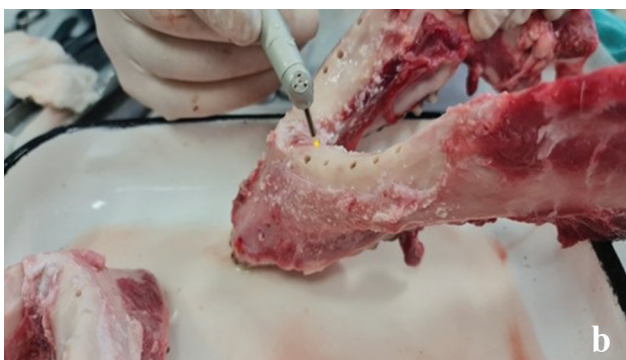

Figure 1. a) Er:YAG laser with a wavelength of 2940 nm (Lite-touch, Light Instruments Ltd, Israel); b) Cavity walls surface irradiation with side firing tip 1.3×19 mm.




Figure 2. The scanning electron microscope chamber (Prisma E SEM, Thermo Scientific, Waltham, MA, USA) with the bone samples.

detector (LVD). The investigations were carried out in the Section of Technology of Dosage Forms and Biopharmacy, Department of Pharmaceutical Sciences at the Medical University of Plovdiv.

Statistical methods

Each study group consisted of 10 samples. Surface deformations of the implant bed were conventionally divided into three locations: apical, median, and marginal (cortical) part. The thicknesses of the smeared layer were measured using scanning electron microscopy (Prisma E SEM, Thermo Scientific, Waltham, MA, USA) for the two groups of experimental samples and a statistical comparison of the results were made.

The quantitative variables were presented by mean and standard deviation (mean±SD) using standard descriptive statistics, and the Shapiro-Wilk test was performed to determine the distribution of the units of observation contained in the sample. Comparisons between two groups were analyzed with the Student's t-tests for independent samples and between more of two groups with one-way ANOVA with Bonferroni correction for multiple comparisons. A 2-sided p-value of <0.05 was considered statistically significant. Statistical analyses were performed using SPSS Statistics v. 26 (IBM Corp. Released 2019. Armonk, NY: USA).

RESULTS

Morphological analysis

Group A: cavities formed with standard implantology drills. The examination of the samples from this group at low magnification (65×) revealed a smooth surface with numerous bone fragments and debris present.

The borders between the osteotomy and the bone were not well defined, and the structure was impaired, with numerous fragments observed in the intratrabecular spaces. This amorphous layer blocked the Volkmann's and Haversian canals (**Figs 3a, 3b**). At magnifications of 120×, 350×, and 1500×, the cavity appeared smooth and completely covered with a smear layer, which had a thickness ranging from 21.77 μm to 136.2 μm. Microcracks resulting from the mechanical trauma caused by the osteotomy could be observed along the entire length.

Group B: implant bed formed by applying a standard method with calibrating implantology drills, followed by surface treatment with an Er:YAG laser by applying the method described above.

Examination of the samples from this group at low magnification (65×) revealed smooth, well-defined borders separating the opening from the adjacent normal bone tissue. The bone surface structure was preserved, with virtually no change in the intratrabecular spaces, as well as




Figure 3. SEM: a) magnification 65x; b) magnification 800x. Cavity surface after standard drilling.

the Volkmann’s and Haversian canals. No traces of melting, carbonization, or organic matter were observed on the border surface. The examination of the samples at higher magnification showed that the osteotomy site was not completely smooth, and an amorphous smear layer with a thickness ranging from 3.054 μm to 47.26 μm was present in certain places. The microcracks observed were shallower and smaller (Figs 4a, 4b).

Statistical analysis

Table 1 illustrates the deformation in microns by location in the implant beds osteotomies using standard drills - the first group and the second group - osteotomies using standard drills and after that Er:YAG laser irradiation. Each study group contained ten samples. Surface deformations are generally classified using the apical, middle, and

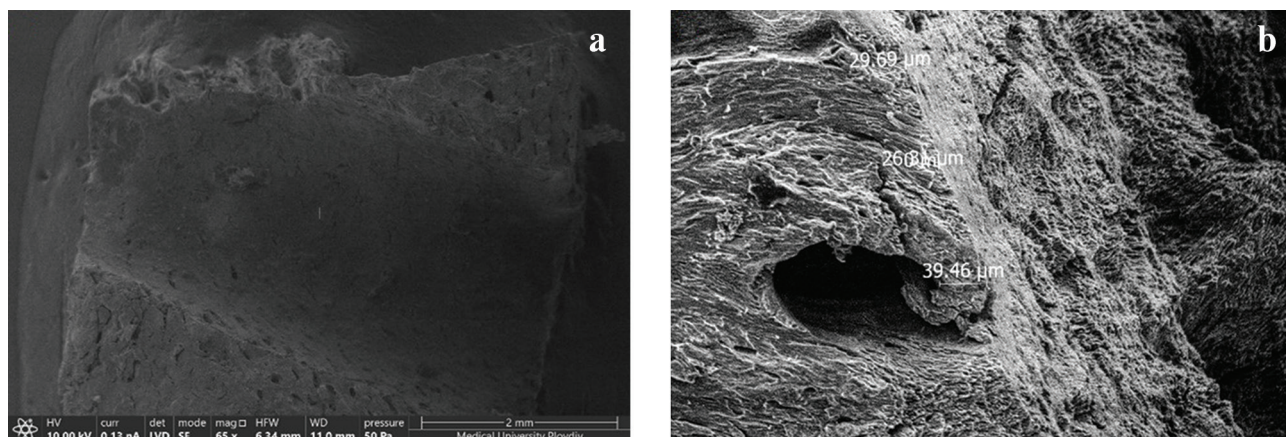


Figure 4. SEM of cavity surface after standard drilling and Er:YAG laser irradiation: a) magnification 65x; b) magnification 800x.

Table 1. Measurements of central tendency and measurements of spread of the deformation measured after standard drill and Er:YAG laser by location

	Mean	Median	SD	Min-max	Range	IQR	SEM
Deformation in implant bed – standard drills (in microns) (n=10)							
Apical	64.52	61.92	28.72	21.77-121.10	99.33	34.32	9.08
Median	79.12	81.61	29.84	31.04-119.50	88.46	48.19	9.44
Marginal	106.65	109.30	20.70	71.16-136.20	65.04	35.06	6.55
Deformation in implant bed – Er:YAG laser (in microns) (n=10)							
Apical	19.50	20.71	11.14	3.05-40.34	37.29	15.67	3.52
Median	18.52	18.61	7.87	5.77-29.54	23.77	14.22	2.49
Marginal	29.52	29.92	11.53	11.31-47.26	35.95	17.99	3.65

marginal (cortical) sections of the implant bed. Despite the small sample size, the favorable outcomes of applying Er:YAG technique of implant bed therapy were noticeable. The bone deformation in the Er:YAG laser-irradiated group was extremely small measured in microns.

Statistically significant differences were observed between mean values by all three locations between the two groups – standard drill vs. Er:YAG laser (Fig. 5).

One-way analysis of variance (ANOVA) was performed to determine whether there are any statistically significant differences between the mean deformations of the implant bed by locations compared within the two groups – implant beds osteotomies only with drills and with drills followed by Er:YAG laser irradiation. Furthermore, when the standard drill technique was used, ANOVA analysis indicated a statistically significant difference in implant bed deformation between the apical and marginal positions (Bonferroni post-hoc test, $p=0.004$). The Er:YAG laser mean deformation values were constant across sites, with no statistically significant differences observed (Fig. 5).

DISCUSSION

A morphological examination of bone tissue following a standard osteotomy and a standard osteotomy followed by biomodification of the surface using an Er:YAG laser were done in this study. The aim was to determine the presence of synergistic effects of the two techniques. The reduction, and in certain places complete absence of a smear layer on the surface of the laser-ablated osteotomy is a result of the thermomechanical action of the laser. The high absorption coefficient of the Er:YAG laser wavelength (2940 nm) by water molecules and hydroxyapatite ions results in almost complete absorption of the delivered energy and an increase in temperature. The heat vaporizes the water, and the internal positive pressure causes microexplosions and tissue ablation. The lateral damage caused by laser radiation is controlled by adjusting the speed of the pulses.^[12]

Faster pulses allow for shorter time for heat conduction to adjacent tissues, minimizing lateral thermal damage. The short pulse mode of operation of the Er:YAG laser chosen for this study meets these conditions. The smear layer is largely or completely removed without affecting the underlying structures.

In experimental porcine rib osteotomy with an Er:YAG laser, Panduric et al.^[4] also found the absence of a smear layer, which potentially improves the adhesion of blood elements at the beginning of the healing process and osseointegration^[5]. According to this author, previous reports have indicated that the smear layer hinders this process.^[6] The same authors performed also a diffraction analysis of Er:YAG laser-treated models, demonstrating the complete absence of any carbonizing effect.

Sasaki et al. treated parietal bones of Wistar rats with an Er:YAG laser and analyzed the results using light microscopy, transmission electron microscopy (TEM), electron diffraction analysis, and energy-dispersive X-ray spectroscopy (SEM-EDX). The study demonstrated a very thin altered layer on the surface of the bone tissue with a thickness of up to 30 μm , which was also confirmed in our study.^[13]

Based on the absence of a smear layer in Er:YAG-laser-treated osteotomies, Lewandrowski et al. concluded that bone healing with this method is faster compared to standard procedures.^[14] Similar findings were also reported by Kesler et al. after Er:YAG laser (2940 nm) treatment of implant sites in rat tibiae.^[15] El-Montaser et al. confirmed faster osseointegration and new bone formation in implant sites treated with an Er:YAG laser compared to standard rotary techniques.^[16]

A disadvantage of Er:YAG laser osteotomy is the presence of inaccuracies in the formed site and the peri-implant space. In addition, achieving sufficient cooling in depth poses a challenge. Schwarz et al. assessed the osseointegration of titanium dental implants in implant sites in Beagle dogs using standard instruments and lasers. The authors performed a histomorphometrical assessment of the osseointegration. Despite the wider peri-implant gaps

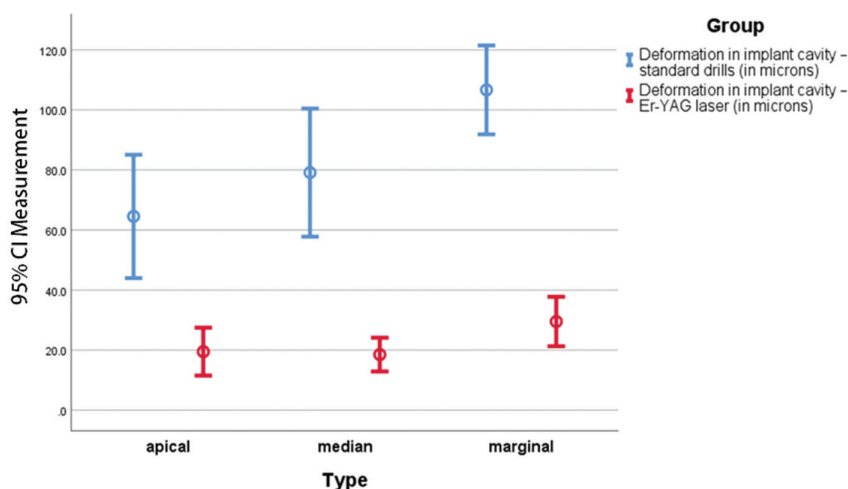


Figure 5. Error bar (95% CI) by location between the two techniques – standard drill vs. Er:YAG laser.

and diameter inaccuracies in the Er:YAG laser group, the results showed higher values of bone-to-implant contact in this group as early as two weeks, and completely new bone formation at twelve weeks.^[17] Seyman et al. reported an increased interest in the use of stereolithographic surgical guides in hard tissue surgery with Er:YAG lasers, aiming to avoid calibration difficulties.^[18]

We did not find studies regarding the combination of the standard rotary technique and Er:YAG laser ablation aimed at synergistic effects, as proposed in this study, in the available literature. Our hypothesis is to optimize the results of titanium screw implant placement following application of Er:YAG laser ablation and biomodification of the bone surface. This approach will lead to wider use of these techniques in implantology. The parameters and settings for this ablation were personally selected by us to eliminate the risk of possible damage to the adjacent bone during laser irradiation and parameters are still being refined. Together with efficient cooling with a ‘tsunami’ effect produced by the cooling liquid, they ensure no damage to the adjacent bone and the removal of the amorphous layer.

The results of the morphological examination of the bone surface using SEM are promising and offer hope for moving forward with a clinical experimental investigation.

CONCLUSIONS

Based on the results of the current study, we believe that the effect of the Er:YAG laser with a wavelength of 2940 nm creating biomodification of the surface of a bone bed for dental screw implants made with standard rotary equipment is synergistic, and the action is potentiating. This is a promising prospect in implantology for achieving faster osseointegration and early functional loading of the implants.

Acknowledgements

The authors have no support to report.

Funding

The authors have no funding to report.

Competing Interests

The authors have declared that no competing interests exist.

REFERENCES

1. Gehrke SA, Aramburú Jr JS, Pérez-Albacete MC, et al. The influence of drill length and irrigation system on heat production during os-

teotomy preparation for dental implants: an ex vivo study. *Clin Oral Implants Res* 2018; 29(7):772–8.

2. Gehrke SA, Treichel TLE, Aramburú Jr JS, et al. Effects of the technique and drill design used during the osteotomy on the thermal and histological stimulation. *Sci Rep* 2020; 10:20737. doi: 10.1038/s41598-020-77762-z
3. Klinger M, Rahemtulla F, Prince CW, et al. Proteoglycans at the bone-implant interface. *Crit Rev Oral Biol Med* 1998; 9:449–63.
4. Panduric D, Juric I, Music S, et al. Morphological and ultrastructural comparative analysis of bone tissue after Er:YAG laser and surgical drill osteotomy. *Photomed Laser Surg* 2014; 32(7):401–8. doi: 10.1089/pho.2014.3711
5. Stubinger S. Advances in bone surgery: the Er:YAG laser in oral surgery and implant dentistry. *Clin Cosmet Investig Dent* 2010; 2:47–62.
6. Visuri SR, Walsh Jr JT, Wigdor, HA. Erbium laser ablation of dental hard tissue: Effect of water cooling. *Lasers Surg Med* 1996; 18: 294–300.
7. Nachkov I, Zagorchev P, Yaneva B. Temperature limits during irradiation in laser-assisted treatment of peri-implantitis – laboratory research. *Folia Med (Plovdiv)* 2023; 65(1):140–8.
8. Tsanova ST, Tomov GT. Morphological changes in hard dental tissues prepared by Er:YAG laser (LiteTouch, Syneron), Carisolv and rotary instruments. A scanning electron microscopy evaluation. *Folia Med (Plovdiv)* 2010; 52(3):46–55. doi: 10.2478/v10153-010-0006-1
9. Yaneva B, Karaslavova E. Erbium-doped yttrium aluminium garnet (Er:YAG) laser instrumentation in periodontal treatment - scanning electron microscope study. *Oxidation Communications* 2021; 44(1):162–70.
10. Shapiro F. Bone development and its relation to fracture repair. The role of mesenchymal osteoblasts and surface osteoblasts. *Eur Cell Mater* 2008; 15:53–76.
11. Fried NM, Fried D. Comparison of Er:YAG and 9.6-microm TE CO₂ lasers for ablation of skull tissue. *Lasers Surg Med* 2001; 28:335–43. doi: 10.1002/lsm.1059
12. Aoki A, Sasaki KM, Watanabe H, et al. Lasers in nonsurgical periodontal therapy. *Periodontol* 2000 2004; 36:59–97. doi: 10.1111/j.1600-0757.2004.03679.x
13. Sasaki KM, Aoki A, Ichinose S, et al. Ultrastructural analysis of bone tissue irradiated by Er:YAG Laser. *Lasers Surg Med* 2002; 31:322–32.
14. Lewandrowski KU, Lorente C, Schomacker KT, et al. Use of the Er:YAG laser for improved plating in maxillofacial surgery: comparison of bone healing in laser and drill osteotomies. *Lasers Surg Med* 1996; 19(1):40–5.
15. Kesler G, Romanos G, Koren R. Use of Er:YAG laser to improve osseointegration of titanium alloy implants - a comparison of bone healing. *Int J Oral Maxillofac Implants* 2006; 21(3):375–9.
16. El-Montaser M, Devlin H, Dickinson MR, et al. Osseointegration of titanium metal implants in erbium-YAG laser-prepared bone. *Implant Dent* 1999; 8:79–85.
17. Schwarz F, Oliver W, Herten M, et al. Influence of implant bed preparation using an Er:YAG laser on the osseointegration of titanium implants: a histomorphometrical study in dogs. *J Oral Rehabil* 2007; 34:273–81.
18. Seymen G, Turgut Z, Berk G, et al. Implant bed preparation with an Er,Cr:YSGG laser using stereolithographic surgical guide. *J Lasers Med Sci* 2013; 4(1):25–32.

Лазерная биомодификация поверхности костного ложа для установки спиральных дентальных имплантатов: исследование на основе сканирующей электронной микроскопии

Николай Каназирски¹, Деян Нейчев¹, Ралица Райчева², Николай Захариев^{3,4}

¹ Кафедра хирургии полости рта, Факультет дентальной медицины, Медицинский университет – Пловдив, Пловдив, Болгария

² Кафедра „Социальная медицина и общественное здравоохранение“, Факультет общественного здравоохранения, Медицинский университет – Пловдив, Пловдив, Болгария

³ Кафедра фармацевтических наук, Факультет фармации, Медицинский университет – Пловдив, Пловдив, Болгария

⁴ Научно-исследовательский институт, Медицинский университет – Пловдив, Пловдив, Болгария

Адрес для корреспонденции: Николай Каназирски, Кафедра хирургии полости рта, Факультет дентальной медицины, Медицинский университет – Пловдив, бул. „Христо Ботев“ № 3, 4002 Пловдив, Болгария; Email: nkanazirski@gmail.com

Дата получения: 24 августа 2023 ♦ **Дата приемки:** 6 октября 2023 ♦ **Дата публикации:** 31 декабря 2023

Образец цитирования: Kanazirski N, Neychev D, Raycheva R, Zahariev N. Laser biomodification of the bone bed surface for placement of spiral dental implants: a study based on scanning electron microscopy. Folia Med (Plovdiv) 2023;65(6):993-999. doi: 10.3897/foimed.65.e111609.

Резюме

Введение: В традиционной хирургии полости рта при остеотомии используются различные вращающиеся и механические инструменты. Несмотря на внедрение эффективных систем охлаждения, трудно предотвратить термическое повреждение прилегающей кости, вызванное теплом, выделяющимся во время процедуры. На поверхности образуется смазанный слой, который может препятствовать взаимодействию элементов крови с подлежащими тканями, что приводит к замедлению процесса заживления.

Цель: В этом исследовании изучается возможность преодоления этих недостатков путём сочетания традиционных методов с импульсным Er:YAG-лазером. Изучая поверхности остеотомии с помощью сканирующей электронной микроскопии (SEM), мы исследовали потенциальные синергетические эффекты, которые могли бы принести пользу традиционной имплантологии.

Материалы и методы: Сплит-остеотомии выполняли на нижних челюстях свежесушенных домашних свиней (*Sus scrofa Domestica*). При исследовании поверхности остеотомии в экспериментальном сравнении участвовали две группы: группа А – стандартная методика и группа Б – абляция поверхности Er:YAG-лазером по собственной методике. Образцы обеих групп были исследованы с помощью сканирующей электронной микроскопии (SEM).

Результаты: В образцах группы А поверхность кости была гладкой, с аморфным слоем и микротрещинами по всей поверхности. Толщина этого слоя колебалась от 21.77 μm до 136.2 μm , полностью перекрывая каналы Volkman и Haversian. В группе Б границы были ровными и чётко выраженными. Костная структура оставалась неизменной, внутритрабекулярные пространства пусты, признаков карбонизации нет, открытые каналы выходят на поверхность. Размер смазанного слоя составлял от 3.054 μm до 47.26 μm , в некоторых местах наблюдалось его полное отсутствие.

Заключение: Настоящее исследование доказывает, что абляция поверхности остеотомии с помощью Er:YAG-лазера приводит к биомодификации за счёт устранения смазанного слоя без изменения параметров костного ложа.

Ключевые слова

биомодификация, Er:YAG-лазер, место имплантации, смазанный слой, SEM
