

Periodontal decontamination in microsurgery

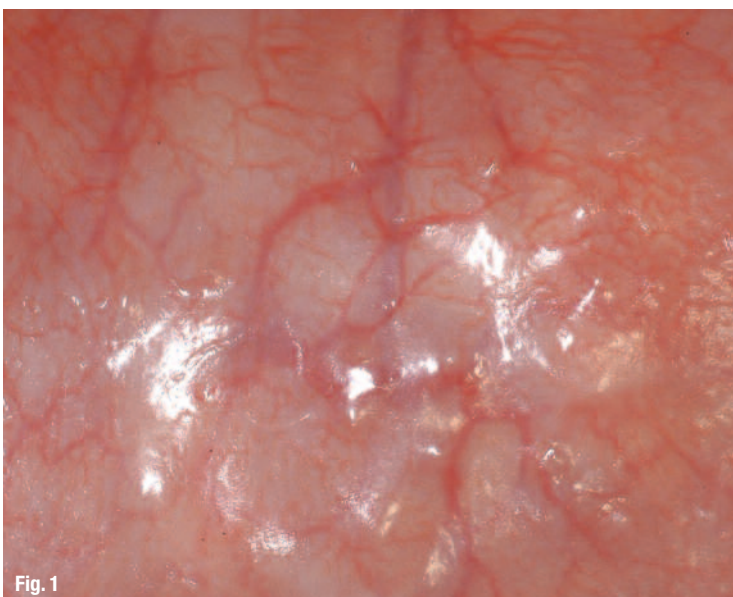
Author_Dr Fabrice Baudot, France

_Introduction

We are witnessing today an upsurge in the use of minimally invasive techniques in the medical field. Dentistry has not escaped this rapidly expanding trend. In all the specialties of our discipline, we see the appearance of micro-dentistry operating instruments and protocols. The search for better operating comfort, greater effectiveness and better results lead us in this direction.

Fig. 1 _This strongly magnified view of the periodontium shows the abundance of the anatomic structures.

Periodontology also became part of this process several years ago with the development of periodontal microsurgery. This approach is based on an adapted technological platform and new operating protocols. The object of this article is to present a new surgical technique made possible by the synergy of



LiteTouch Erbium-YAG laser (Syneron Dental Lasers, Israel) and optical aids.

_Basic aspects of the microsurgery

Why microsurgery? This is a legitimate question.

Preserving vascularization

Burkhardt & Lang in 2005 clearly showed that a microsurgical technique led to better healing than the classical technique.¹ The key to the success of microsurgery is maintaining the integrity of the tissues and in particular their vascularisation – so much so that a surgical technique can be qualified as minimally invasive when it safeguards tissue vascularisation.

Plane-by-plane surgery

In this type of surgery, attention must be paid to the thinness of the anatomic structures, namely of the different tissue planes being operated on. Just as plastic surgeons treat skin tissues plane by plane, the periodontist should handle the periodontium in the same way, taking account of the anatomic and functional specificity of each plane. The thinness of the structures to be operated on calls for a microsurgical approach.

Avoiding tissue tension

With plane-by-plane surgery it is possible to respect the various anatomic structures, as well as to manage possible tissue tensions that could be harmful to the revascularisation of the surgery site, as brilliantly demonstrated in Mammoto's article published in the well-known Nature review in 2009.² The development of endothelial cells, seat of the vascularisation process, is influenced by tension receivers

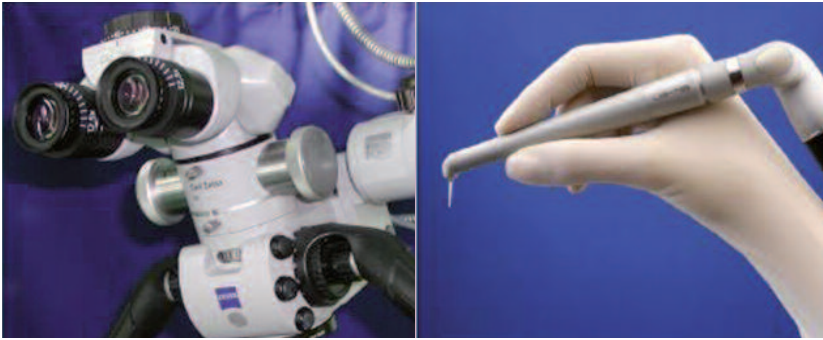


Fig. 2_The synergy of two instruments used in periodontal microsurgery.

which guide the tissue morphology in particular during tissue healing.

Fine suturing or no suturing

This is yet another surgical parameter in respect of the surgically treated tissues. Fine sutures have physical and biological properties. They avoid excessive tissue tensions, therefore ensuring better healing,³ and they limit microbial infiltration of the operated areas.⁴ With the microsurgical use of the Lite-Touch Erbium:YAG laser it is possible to operate without need of sutures, which is even less traumatic.

Avoiding periosteum detachment

The periosteum is a fundamental vascular source for the periodontium. Full thickness flaps, or even partial thickness flaps, induce a delay in healing and bone resorptions, as noted in the recent study by Fickl et al.⁵ Flapless surgery or surgery using partial thickness techniques considerably improves the healing process: this has long been studied⁶⁻⁸ and is made possible precisely by microsurgical techniques.

Advantage of the LiteTouch Erbium:YAG laser in periodontal microsurgery

Fig. 3_ Laser absorption curves.

As can be seen, the dental practitioner must im-

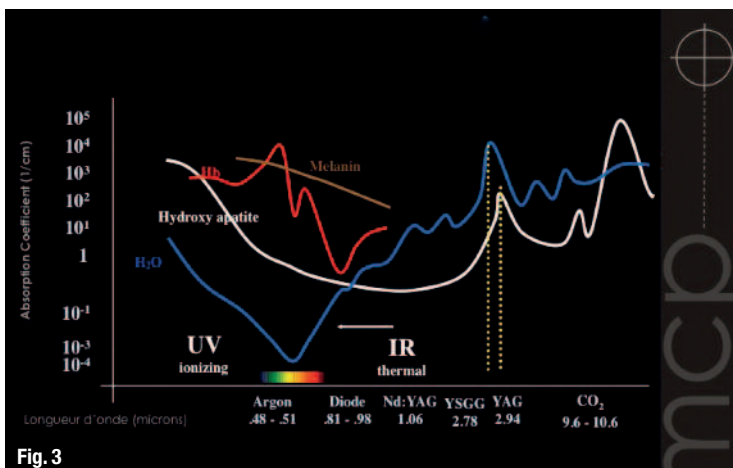


Fig. 3

prove his view of the tissues on which he is operating, but he must also have tools that can meet the requirements of more precise movements.

The synergy created between optical aids and Erbium:YAG laser advantageously meets this dual requirement. Thanks to optical aids (minimum x 3.5), the surgeon acquires a finer analysis of the tissues on which he is operating and the accuracy of the therapeutic effects of the LiteTouch Erbium:YAG laser allows him the optimal precision required for a minimally invasive surgical approach.

The main feature of the energy released by the laser beam at a wavelength of 2940 nm is its massive absorption by water and hydroxylapatite. This physical property gives this laser its great versatility in dental surgery and especially in periodontology.

The energy absorbed in the targeted tissues leads to their vaporisation: visually, a tissue micro-ablation process is observed. The laser becomes a microsurgical instrument that allows precise sculpting of the tissues. The micro-ablation results depend on the water load of the targeted tissues. The greater the water load, the more intense the vaporisation. The water load of the various tissue planes is not constant. For purposes of clarity, two types of situations can be distinguished:

Increasing water load

Hard tissues against soft tissues: in such a situation, the Erbium:YAG laser is more delicate to use, with high risk of injuring the soft tissues. In these clinical cases, piezosurgery (complementary to laser) seems to be more adapted.

- Opening of the sinus flaps
- Root haemisection
- Bone grafting

Decreasing water load

Soft tissues against hard tissues: This is the optimal field of application of the Erbium:YAG laser. Radiation acts on the soft tissues (which contain more water) without affecting the hard tissues (which contain less water). The appropriate clinical situations are for example:

- Gingivectomy against the root
- Tissue degranulation against the bone and the roots
- Inflammatory tissues inlaid on the healthy gum

These concepts define the field of application and mode of operation of the Erbium:YAG laser in periodontology. Laser treatment of periodontal tissues differs from surgery with conventional instruments.

Fig. 4 a) intra-operative view with microsurgical access to the deep periodontium: aggressive periodontitis. Note the tissue stability at two months; b) post-operative view after two months; c) Post-operative view (two months) of an aggressive periodontitis treated by microsurgical protocol and flapless PRF. Note the access to oral hygiene and the tissue stability

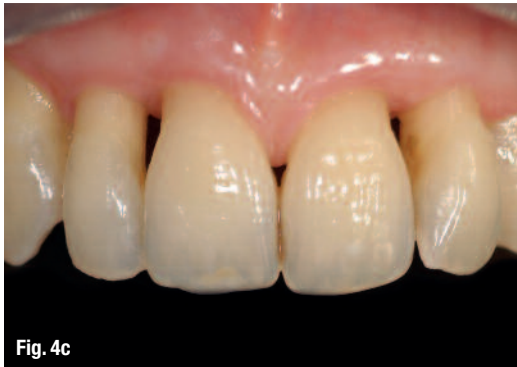
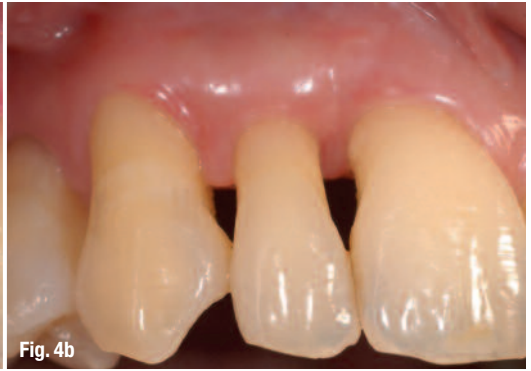
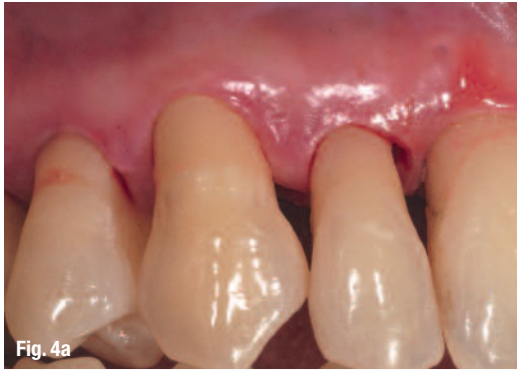Fig. 5 Pre-operative x-ray of an aggressive periodontitis, in smoker patient, 45 years old with Vitamin D deficiency.

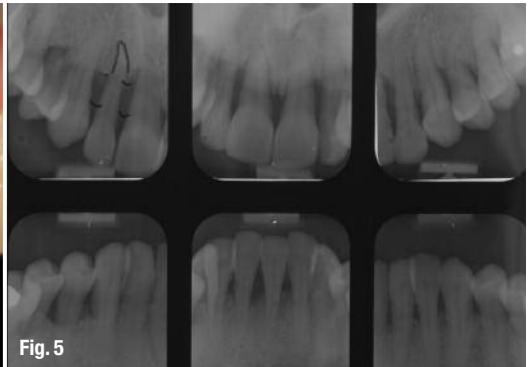


Fig. 6 After cleaning of the deep periodontium, a very light polish of the root surfaces may be performed under visual control.

No more cutting or drilling of the tissues, but very accurate sculpting. The beam is used as a sort of optical curette with selective action on the inflammatory tissues, leaving the surrounding tissues undamaged, and particularly preserving vascularisation.

Erbium:YAG laser setting parameters

Here is not the place for explanations of laser physics; it should be noted only that the Erbium:YAG laser operates in pulse mode. Energy is released by pulses with water irrigation.

NB: the irrigation can be suspended, but thermal effects appear rapidly. This allows coagulation with the Erbium:YAG laser which, in principle, is not intended for this. The practitioner has five parameters at his disposal to adjust the therapeutic laser effect.

Two parameters set on the device

To simplify the clinical use, the manufacturers

have limited the device setting to two parameters to be defined by the practitioner in order to determine the characteristics of the beam emitted: pulse frequency (in Hertz) and pulse intensity (in millijoules). The result of these two parameters is a pulse power measured in watts.

Three variable parameters in the practitioner's hands

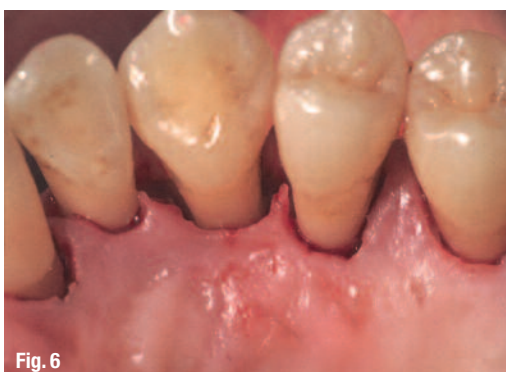To adjust the energy delivered to the targeted tissues, the practitioner will utilise the following parameters:

- Pulse duration
- Distance between the energy emitting source and the tissues
- Beam angulation

By regulation of these parameters, the practitioner takes full advantage of the "magic" effect of the instrument. With visual control, he will be able to sculpt the tissues with an accuracy of some tens of microns.

Microsurgical decontamination protocol

The use of such microsurgical instruments, the improvement of optical aids and the development of our knowledge of the importance of micro-vascularisation in the healing process provide us today with a third way between the surgical approach advocated by the Americans, especially by Widman,⁹ and the completely non-surgical techniques proposed by the Swedes from the 1990s.¹⁰ Both ap-



proaches are efficient, but their limits have been shown in the treatment of periodontitis:

- The surgical approach is invasive, the surgical protocols are complicated and the long treatment periods expose to risks of reinfection. While the aim is to reduce the periodontal pockets, the periodontal decontamination surgery does not obviate the need for a strict maintenance programme.
- The non-surgical approach follows a microbiological rationale. Acting on the aetiology of the pathology and respecting the periodontal tissues, it has achieved good results. However, the surgical technique results in a large number of residual periodontal pockets and the non-surgical treatment of periodontitis entails an ultra-strict maintenance programme that few patients and members of the medical staff are able to maintain in the long term (especially in France where there are no dental hygienists). The way opened by the microsurgical approach is expected to combine the advantages of both techniques while smoothing out their disadvantages. This way derives from the technique pioneered by Yukna (1978) who published "E.N.A.P: Excisional for New Attachment Procedure".¹¹

Finally, the most important element in periodontitis treatment is periodontal maintenance. The patient must have access to all the dental surfaces in order to maintain a level of hygiene adapted to his physiological profile. The critical point lies in the number of periodontal pockets. The initial phase aims at reaching the deep periodontium in order to clean these pockets (non-surgical approach) and to some extent to reduce them (surgical approach).

The microsurgical approach proposed will meet both criteria in a simple, quick surgical protocol.

The practitioner works with optical aids and therefore with visual control, with an ultra-fine surgical instrument which allows him to operate in a non-invasive, flapless way, while preserving tissue vascularisation and integrity.

Three-step surgical protocol

- Internal bevel sulcular incision (more or less shifted) to access the deep periodontium. This incision may be done with a fine diamond drill (flame shape) or with a laser in the most delicate areas. The

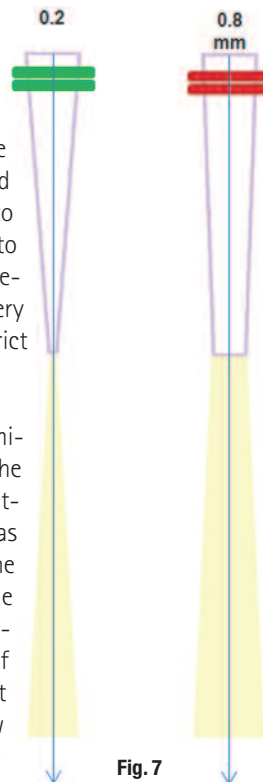


Fig. 7

object is to provide access to the deep periodontium (a sort of access cavity). Through this 1 mm space, it is possible to see up to 10-12 mm with high performance optical aids. Therefore, it is possible to operate with visual control without needing to detach a flap.

- Cleaning the deep periodontium is conventionally done using fine ultrasound to remove tartar. Inflammatory tissues are laser treated by selective vaporisation. The fine laser insert gives access through a widened sulcus, which will allow accurate tissue degranulation like a very high performance curette.
- At this stage, the operation is over. The surgical protocol is short, minimally invasive and the post-operative management light.

Treatment of the whole mouth is proposed in two sessions, 48 hours to one week apart at most in order to limit the risks of cross contamination. Each half-mouth (top and bottom) surgical session takes between 45 minutes and 1h30 according to the extent of the lesions. Oral hygiene teaching sessions are given on a decontaminated periodontium.

Two months after surgery, the patient pays a follow-up visit for reassessment. At this stage, the adapted periodontal maintenance programme will be established and begin. It will be reassessed yearly according to the evolution of the clinical parameters.

The periodontitis treatment in such a protocol is simple. The periodontal maintenance is rapidly initiated on a periodontium that has been treated deeply and efficiently. The microsurgical protocol is halfway between the surgical and non-surgical approaches.

Selective tissue vaporization with Erbium:YAG laser and therapeutic properties

As already shown, one of the special features of this surgical protocol is the use of the Erbium:YAG laser which provides therapeutic efficiency in a restricted space. The characteristic of tissue micro-ablation according to the water load of the tissues allows fine and selective degranulation of the tissues, plane by plane, thus respecting the principles of microsurgery. Inside the periodontal pocket, the

Fig. 7_Defocussing effect of the tip.

laser pulses vaporise the inflammatory tissues. The first vaporized tissue planes are moisturised and infiltrated most. Under the effect of laser irrigation, the surgical site clearly emerges and the practitioner, with optical aids, can see the surfaces he or she is treating. There is no coagulation and therefore no micro-vascular lesion, but the removal of inflammatory tissues reduces bleeding and makes the surgical site clearer.

Once the inflammatory tissues are removed, the practitioner has a precise view of the pocket inside and can treat the second plane, the healthy tissues. At this stage, soft tissue plasty of the pocket may be considered to reduce depth in the sectors where this is possible. Then, the practitioner may carry out micro bone remodelling directly from inside the pocket, by tissue micro-ablation: flapless bone modelling. Laser beam angulation using the defocusing cone allows low-energy treatment of the side walls of the pocket: ligament and bone. These walls will be decontaminated and bio-stimulated according to the LLT laser principles: low level therapy. The Erbium:YAG laser absorption by the hydroxylapatite gives this radiation excellent properties for the cleaning of the bone surfaces, removing the smear layer caused by alveolysis.

The periodontal debridement by laser is performed with water irrigation. We benefit from the agitation of the irrigation solutions, as is the case in endodontic applications of the laser. The laser-triggered microcavitation of the irrigation cleans the walls of the space thus treated.

__The Erbium:YAG laser in the clinical practice

The Erbium:YAG laser beam emission inside the periodontal pocket is accompanied by physical and biological phenomena with therapeutic effects visible under high magnification. The laser is a surgical instrument with much higher performance than conventional instruments which have only a mechanical and relatively basic action in comparison with this radiation. In practice, it is all very simple. The laser tip is inserted into the pocket just like an optical curette, and the practitioner scans the surfaces to be treated while the beam is emitted in order to limit the thermal effects and to carry out a uniform and homogeneous treatment (similarly to a paint spray). The ergonomics of the insert allow visual control of the therapeutic effects. The tissue plasty requires applications in the scanning movement. To increase the surfaces to be treated, the practitioner defocuses radiation. The three parameters of time of exposure, focal distance and beam angulation are the variables at the practi-

tioner's disposal to express his treatment expertise.

__Conclusion

More than ten years ago, the scientific literature proved the physical and biological properties of the Erbium:YAG laser: it is a high performance, safe surgical instrument. The main advantage of this radiation lies in its high absorption by water. This is what makes it safe since it limits the collateral thermal effects. Its clinical performance can be attributed to its tissue micro-ablation properties. It is a versatile instrument allowing sculpting of enamel at the highest energy levels, and surface decontamination through its bactericidal effects on microbial biofilms, at lower energy levels.

We have described here the application of the Erbium:YAG laser in periodontal decontamination, but its field of application is not limited to periodontics. The Erbium:YAG laser is also used in plastic surgery. It allows performing of surgery, no longer by cutting or drilling tissues, but by sculpting them. Micro-plastic procedures can thus be carried out on soft tissues in mucogingival surgery, flapless crown lengthening and other minimally invasive, guided bone regeneration surgeries.

The LiteTouch Erbium:YAG laser is not a treatment, but a microsurgical instrument which, combined with optical aids, offers an additional advantage to dental surgeons who wish to offer minimally invasive treatment.

__contact

laser

Dr Fabrice Baudot

dental@syneron.com
www.synerondental.fr