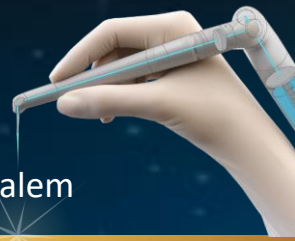

Endo Treatment #2

By Prof. Adam Stabholz

The Hebrew University-Hadassah School of Dental Medicine, Jerusalem

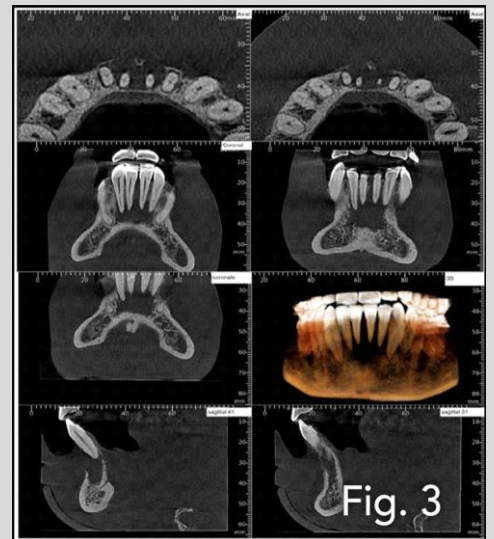
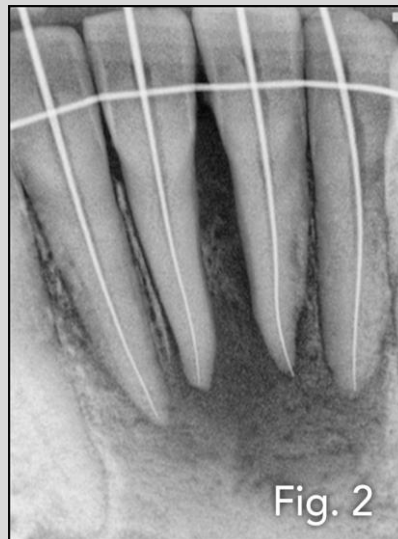
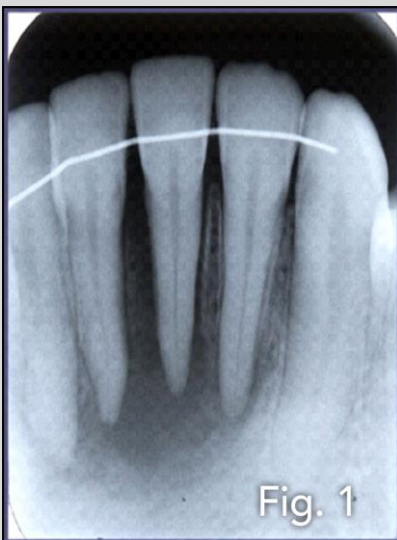

Description:

A male, 30 years old. His medical history revealed a trauma to the lower jaw some years ago during a basketball game.

Before treatment:

The X-Ray images showed an acute dento-alveolar abscess, after drainage, in the anterior region of the lower jaw



Diagnosis:

Acute dento-alveolar abscess through non-vital lower incisors

Chosen treatment:

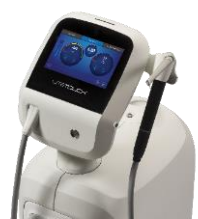Endodontics

Parameters:

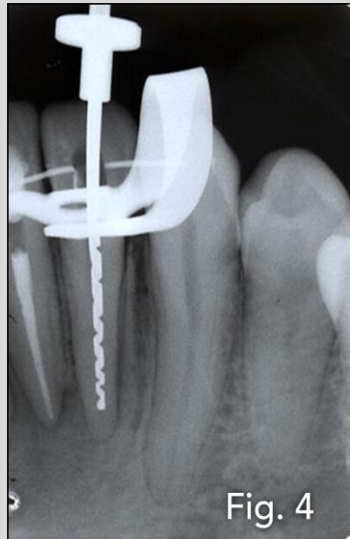
200mJ 12Hz

Tips used:

New Side-Firing
Endo Tip



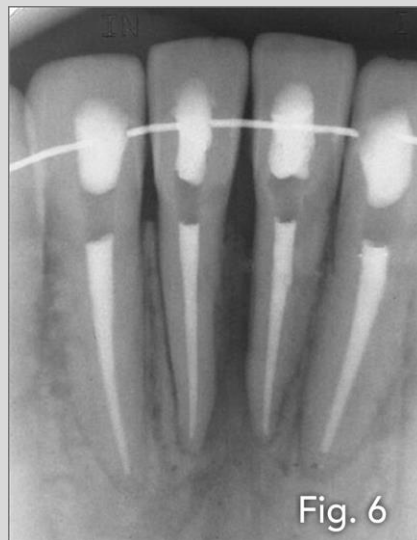
Treatment:



Bio-mechanical instrumentation was completed in all four lower incisors and the Endo Tip (with laser irradiation of 200mJ and 12Hz for 60 seconds in each one of the incisors) was used to achieve thorough disinfection of the root canal system

Follow-up:

6 Months Follow Up



A six months follow up radiograph demonstrates nice healing of the periapical lesion around the lower incisor with no symptoms