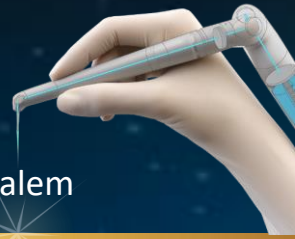

Endo Treatment #1

By Prof. Adam Stabholz

The Hebrew University-Hadassah School of Dental Medicine, Jerusalem

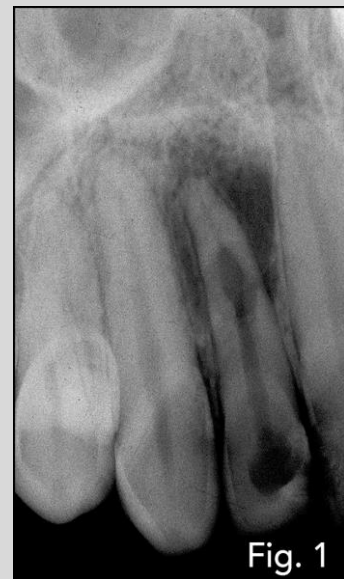

Description:

A female, 18 years old, in good health.

Before treatment:

X –Ray revealed an internal resorption with periapical radiolucency



Diagnosis:

Acute dento-alveolar abscess originates from the right lateral incisor.

Chosen treatment:

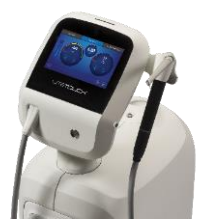Endodontics

Parameters:

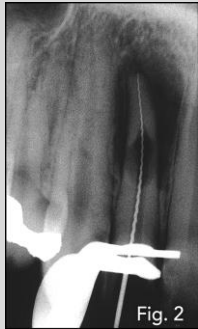100mj 20Hz

Tips used:

New Side-Firing
Endo Tip

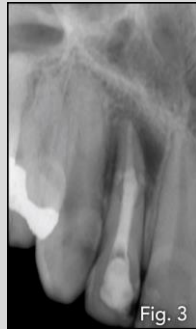

Treatment:



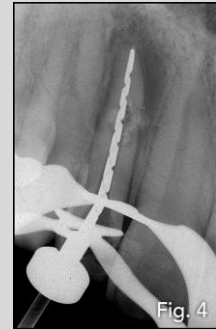
Step 1:

The tooth was opened for drainage and a length measurement x-ray that was taken showed a possible perforation in the resorption area



Step 2:

Antibiotics were prescribed and a week later after all symptoms subsided Ca(OH)₂ was placed for 3 months

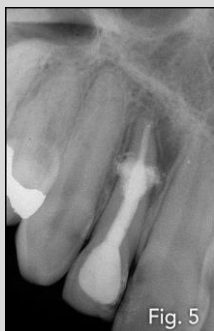

Step 3:

When the patient came back, bio-mechanical instrumentation was completed and the Endo Tip – the new side-firing spiral tip for endodontics was used to achieve thorough disinfection of the root canal system

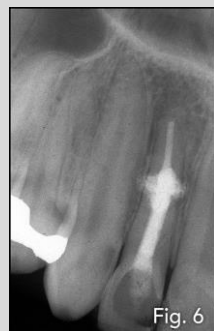Follow-up:

6 Months Follow Up



Six months follow x-ray shows a substantial decrease of the periapical lesion

3 Years Follow Up



3 year follow-up radiograph could demonstrate complete healing