

Treatment of black hairy tongue

Authors: Prof. Georgi T. Tomov, Michail Batilas & Pavlos Spyranitis, Bulgaria

Black hairy tongue (BHT) is a benign medical condition characterised by elongated filiform papillae with typical appearance of the dorsum of the tongue.¹ Its prevalence varies ranging from 0.6 to 11.3 per cent.²⁻⁴ Known predisposing factors include smoking, excessive coffee/black tea consumption, poor oral hygiene, xerostomia, and antibiotics use.^{5,6} Complications of BHT (burning mouth syndrome, halitosis, dysgeusia) respond poorly to conventional therapy.^{1,7} The treatment of BHT involves the identification and discontinuation of the offending agent, modifications of chronic predisposing factors, patient's reassurance to the benign nature of the con-

dition, and maintenance of adequate oral hygiene with gentle debridement to promote desquamation.

The use of antimicrobial therapies, topical triamcinolone acetonide, gentian violet, salicylic acid, vitamin B complex, thymol, and topical or oral retinoids, as well as keratinolytics (podophyllin), topical 30 per cent urea solution, and trichloroacetic acid have been reported in the literature, although potential side effects from local irritation and possible systemic absorption are important factors to consider.^{1,7} In the available literature, lasers are not reported as therapeutic modality for the treatment of BHT.

The aim of this article is to report about a new approach applied in the treatment of BHT, using a combination of laser ablation with Er:YAG laser and toluidine blue-mediated photodynamic therapy (PDT) with diode laser.

Case report

A 37-year-old female patient complained about an abnormal appearance of her tongue of seven months duration. The patient noted a bad taste in her mouth. Shortly before the oral complaint onset she was prescribed antibiotics for sinusitis. Additionally, the pa-

Fig. 1: Appearance of patient's tongue on initial presentation.

Fig. 2a: The "chisel" tip is positioned parallel to the dorsal plane in order to cut the papillae without damaging the tongue.

Fig. 2b: Visible borderline between ablated and no ablated area.

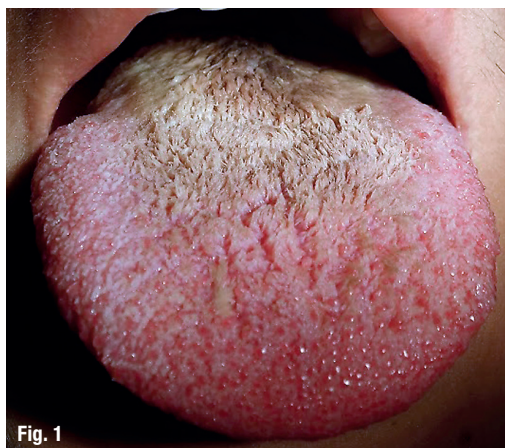

Fig. 1

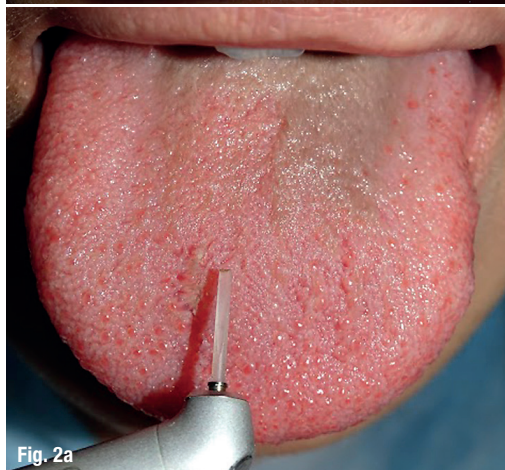


Fig. 2a

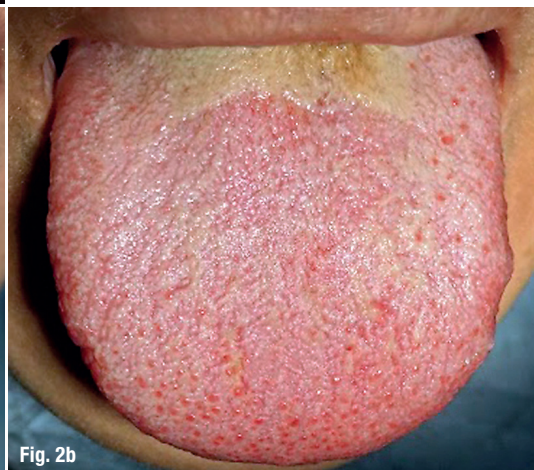

Fig. 2b

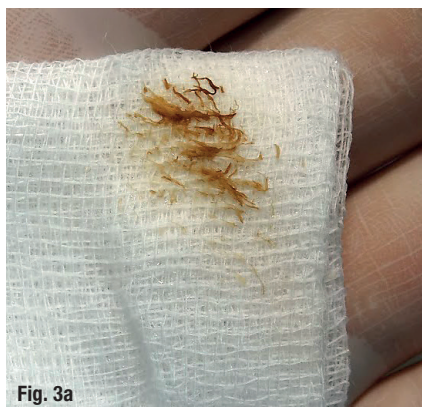

Fig. 3a

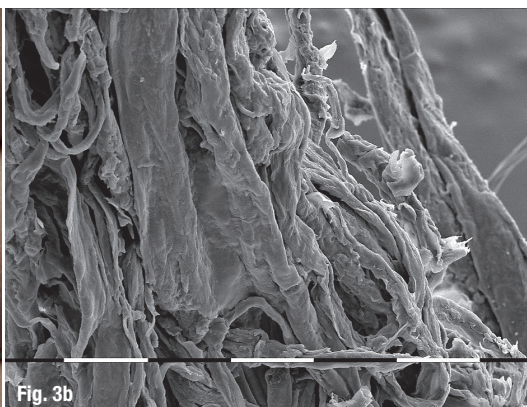


Fig. 3b

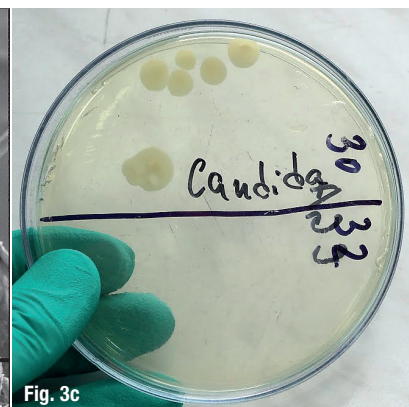


Fig. 3c

tient smoked more than one pack of cigarettes per day. Physical examination demonstrated a light brown, "furry" dorsal surface on the tongue (Fig. 1). The patient was diagnosed with black hairy tongue. After obtaining a written consent by the patient, a new approach was applied to treat the condition using a combination of laser ablation with Er:YAG laser and methylene blue-mediated photodynamic therapy (PDT) with diode laser.

Ablation therapy

During the first treatment session, the elongated papillae were ablated with Er:YAG laser (LiteTouch, Light Instruments, Israel) using "chisel" tip at the following parameters: 200 mJ/18 Hz (3.6 W) with water cooling. Only topical anaesthesia with 10 per cent lidocaine spray was performed prior to the procedure (Figs. 2a & b). The removed papillae were microbiologically tested and evaluated under SEM (Fig. 3).

Toluidine blue-mediated photodynamic therapy

The laser ablation of the elongated papillae of the tongue enhanced the consequent PDT (one day after) due to the better penetration of laser light and spread-

ing of the photosensitiser over the affected area. Five sessions of PDT were performed with the toluidine blue photosensitiser at a concentration of 0.5 per cent applied on the dorsum of the tongue. After five minutes of pre-irradiation time for photosensitiser penetration, the excess was removed and laser activation was done with infrared (890 nm and wavelength of aiming beam 635 ± 10 nm) diode laser (LITEMEDICS dental laser, LAMBDA SpA, Italy) using a bleaching handpiece at 0.5 W (cw) for 60 seconds (Fig. 4).

Results

Follow-up examinations one month as well as three, six and twelve months later revealed significant improvement of the condition with no signs of relapse (Fig. 5).

Discussion


The pathophysiology of BHT has not been fully elucidated.^{1,7} Defective desquamation of the dorsal surface of the tongue is described in a SEM study.⁸ Our findings confirmed these conclusions. This morphology prevents normal debridement, leading to an

Fig. 3: The removed "hairs" (a) observed under SEM (b) are highly elongated cornified spines that result from delayed desquamation of the cells in the central column of filiform papillae and marked retention of secondary papillary cells. The microbiological tests revealed *Candida albicans* infection (c).

ANZEIGE

Publish your expertise!

Become an author for **laser**—international magazine of laser dentistry



Please contact: Georg Isbaner · Editorial manager
g.isbaner@oemus-media.de

© Peshkova/Shutterstock.com




Fig. 4: Toluidine blue-mediated photodynamic therapy (PDT) with diode laser.

Fig. 5: Appearance of patient's tongue after six months of therapy.

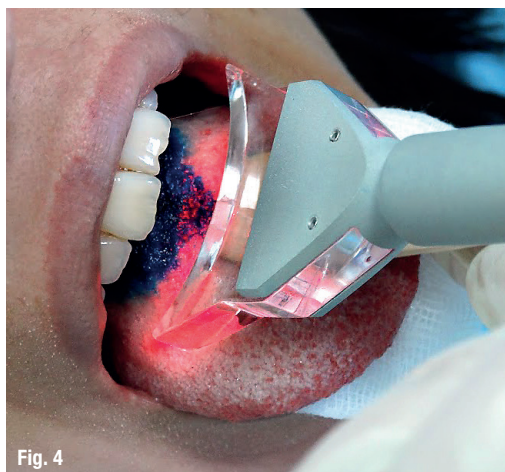

Fig. 4

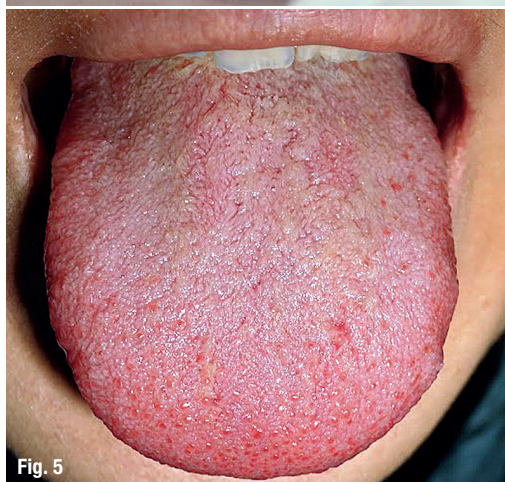


Fig. 5

accumulation of keratinised layers so the elongated papillae secondarily collect fungi and bacteria. Our patient was also positive for *Candida albicans* that is easily harboured in this retentive niche. For these reasons, the therapy effectiveness depends on the ability to remove the hyperkeratinised layer for a better antifungal therapy.

In the available literature, many treatment modalities exist, which generally means that the existing methods are ineffective.^{1,7} The efficacy of tongue scraping is also questionable. The benefits of the pro-

posed combined laser therapy include mechanical removal of the papillae by ablation with Er:YAG laser and consequent local photodynamic therapy. Photodynamic therapy (PDT) has been investigated as a potential antimicrobial therapy and an alternative tool against some infectious diseases in the oral cavity.⁹ The toluidine blue photosensitiser used in this study is absorbed well by the aiming beam of 635 nm. Similarly to methylene blue, toluidine blue has a low antiseptic effect.

Conclusion

There are many possible causes of BHT. It is important for the clinician to take an accurate and detailed history in order to determine the most likely causal agents. The treatment should be individualised, based on the clinician's assessment of the aetiologic agents. This case demonstrated a successful resolution of the condition using combined laser therapy. This new modality offers possibilities for both removal of the papillae by ablation and consequent local photodynamic therapy with pronounced antifungal effect.

contact

Prof. Georgi T. Tomov

DDS, MS, PhD

Associate Professor and Chair of

the Department of Oral Pathology,

Faculty of Dental Medicine

Medical University of Plovdiv, Bulgaria

dr.g.tomov@gmail.com

Author details



Literature



Kurz & bündig

Die schwarze Haarzunge (engl. black hairy tongue; BHT) ist eine harmlose Erkrankung, die gekennzeichnet ist durch eine Verlängerung der Papillae filiformes, mit einem haarigen und dunklen Belag auf dem Zungenrücken.¹ Die Prävalenz zur Entwicklung von BHT liegt zwischen 0,6 und 11,3 Prozent.²⁻⁴ Begünstigt wird die Erkrankung durch Faktoren wie Rauchen, übermäßiger Kaffeeconsum, schlechte Mundhygiene sowie die Einnahme von Antibiotika.^{5,6} Bei der Therapie geht es vor allem darum, die krank machenden Erreger zu beseitigen. Ein neuer Ansatz in der Behandlung von BHT ist dabei die Kombination aus Laserablation mit dem Er:YAG-Laser und Toluidinblau-vermittelter photodynamischer Therapie (PDT) mit dem Diodenlaser. Im Falle einer 37-jährigen, weiblichen Patientin konnte die schwarze Haarzunge durch einerseits Beseitigung der Papillen mittels Laserablation und andererseits consequent lokaler photodynamischer Therapie mit stark antimykotischer Wirkung erfolgreich behandelt werden.