

JACEK MATYS^{1, A–D}, MARZENA DOMINIAK^{2, E, F}

Assessment of Pain When Uncovering Implants with Er:YAG Laser or Scalpel for Second Stage Surgery

¹ Private Dental Practice, Wschowa, Poland

² Department of Dental Surgery, Wrocław Medical University, Poland

A – research concept and design; B – collection and/or assembly of data; C – data analysis and interpretation; D – writing the article; E – critical revision of the article; F – final approval of article

Abstract

Background. Different methods aimed at decreasing pain during some soft tissue procedures in dentistry are still under research. Modern devices as lasers could be a method to reduce the pain and duration of second stage implant surgery.

Objectives. To assess the pain and the impression quality when uncovering implants with a laser and with a scalpel.

Material and Methods. The analysis included 60 implants (Dentium SuperLine, Suwon, Korea) in 30 patients (23 women and 7 men) aged 25–69. In the experimental group, 30 implants were uncovered by means of an Er:YAG laser (LiteTouch[®], Syneron Dental, Yokneam, Israel) with the following fixed operation parameters: 300 mJ, 18 Hz, water cooling at 40%, energy density per pulse: 38.21 J/cm², tip size: 1.0 × 17 mm, distance: 2 mm, tip angle set at 70°, no anesthesia. As a control, 30 implants were uncovered using a scalpel and topical application of 20% benzocaine. An 11-point numeric pain rating scale (NRS-11) was used to evaluate the pain level. A 3-point prosthetic impression scale (PIS) designed by the authors was used to assess the quality of the impression of the implant emergence profile.

Results. The mean value of pain assessed on the NRS-11 for the Er:YAG laser and scalpel were 2.6 and 6, respectively. The mean value of pain for the laser and scalpel at a supracrestal height of periimplant soft tissue (SHPST) ≤ 3 mm were 1.8 and 4.7 respectively, and for SHPST > 3 mm the values were 3.3 and 7.4, respectively. The implant emergence profile impression showed satisfactory or ideal quality in 26 cases.

Conclusions. The use of Er:YAG laser reduces pain and allows minor surgical procedures to be carried out without anesthesia. The impression quality is satisfactory for the preparation of prosthetic reconstructions (*Adv Clin Exp Med* 2016, 25, 6, 1179–1184).

Key words: pain, NRS-11 scale, Erbium:YAG laser, PIS scale, emergence profile.

Soft tissue ablation with the use of lasers has been widely described in scientific papers. Many clinical studies have confirmed that using erbium: yttrium, aluminium, garnet (Er:YAG) lasers reduces pain during surgery and ensures better wound healing afterwards [1, 2]. Clinical trials have also shown the positive impact of erbium, chromium:yttrium-scandium-gallium-garnet (Er,Cr:YSGG) lasers on decreasing swelling, edema and scarring, as well as providing better coagulation [1–3].

There are two hypotheses explaining reduced pain during the removal of soft tissue with an Er:YAG laser. The first theory hypothesizes the creation of a protective layer due to protein coagu-

lation caused by the laser light, whereas the second one posits sealing of nerve endings in the immediate zone of laser beam operation [4].

Studies of Er:YAG lasers have proven their effectiveness in destroying bacteria living on teeth and implants, maintaining the sterility of the treatment area and ensuring bio-stimulation, vaporization, coagulation and photoablation of the treated tissues [5–8].

Er:YAG lasers may be successfully used to surgically remove small lesions on the oral mucous membrane without anesthesia [8, 9]. Safe application of an Er:YAG laser on the implant surface also provides an alternative to traditional mechanical curettage in treating perimplantitis [10, 11].

Different techniques can be used for second stage implant surgery, e.g. uncovering with a scalpel, tissue punch or laser. Identification of a patient's periodontal biotype has a fundamental meaning in the optimal planning of therapeutic management in implantology [12]. The sufficiency of the attached gingiva (AG) around fixed restorations is the key factor in choosing a technique for uncovering implants [13]. When the attached gingiva around implants are sufficiently thick, the implants can be uncovered without subepithelial connective tissue grafts (SCTG) or free gingival grafts (FGG) [14–16].

Pain scales are based on self-reporting, observational or physiological data. The most useful ones in dentistry for adults include numeric rating scales (NRS), visual analog scales (VAS) and verbal rating scales (VRS). All of these scales allow the differences in pain reported after dental treatment to be assessed, and they can be a valid and reliable tool in clinical dental practice [17]. The 11-point Numeric Rating Scale (NRS-11), where 0 stands for no pain and 10 for the most severe pain, has good sensitivity and generates data that can be statistically analyzed for scientific purposes [18, 19].

The aim of this study was to evaluate the level of pain felt during second stage implant surgery using an Er:YAG laser (LiteTouch[®], Syneron Dental, Yokneam, Israel) and using a scalpel in relation to the supracrestal height of periimplant soft tissue (SHPST). The quality of the prosthetic impression of the emergence profile made by means of the erbium laser was also assessed.

Material and Methods

The study group was recruited from among patients of the NZOZ Ka-dent private healthcare facility in Wschowa, Poland, who were treated with implants in 2013 and 2014. The analysis covered 60 implants (Dentium SuperLine[®], Suwon, Korea) in 30 patients (23 women and 7 men), aged 25–69, with partial edentulism in the left and right

mandibular regions and sufficient dimensions of keratinized mucosa around the implants. Patients affected by severe systematic diseases, uncompensated diabetes or uncontrolled periodontal disease, and those smoking more than 10 cigarettes daily, were excluded from the study. All the patients in the study had good oral hygiene and sufficient bone volume to allow dental implant insertion. All the patients signed an informed written consent form. The clinical trial was carried out in accordance with the Declaration of Helsinki.

The patients were treated with dental implants between 10–12 mm in length and 4.5 mm in diameter. The implants were uncovered three months after surgery using the Er:YAG laser on the left-mandible implants (the experimental group) and using a scalpel on the right-mandible implants (the controls). The implants from experimental group were uncovered one week before the controls to assess the pain scores separately.

In the experimental group, 30 implants were uncovered using the Er:YAG laser with the following fixed operation parameters: 300 mJ, 18 Hz, water cooling at 40%, energy density per pulse: 38.21 J/cm², tip size: 1.0 × 17 mm, distance: 2 mm, tip angle set at 70°, no anesthesia. In the control group, 30 implants were uncovered using a scalpel and topical application of 20% benzocaine.

The pain experienced by the patients was evaluated on the NRS-11 scale, on which a rating of 0 means no pain, 1–3 stands for mild pain, 4–6 is moderate pain and 7–10 is severe pain. The study assumed that if pain was greater than 7 (severe pain), anesthesia should be administered or method of tissue ablation changed from laser to a traditional method or vice versa.

A prosthetic tray was used to take an impression with a transfer abutment. The accuracy of the implant emergence profile was assessed visually on a 3-point prosthetic impression scale (PIS) designed by the authors (Fig. 1), where 1 is ideal projection of the soft tissue (no bubbles or scratches), 2 is satisfactory projection of the soft tissue (small

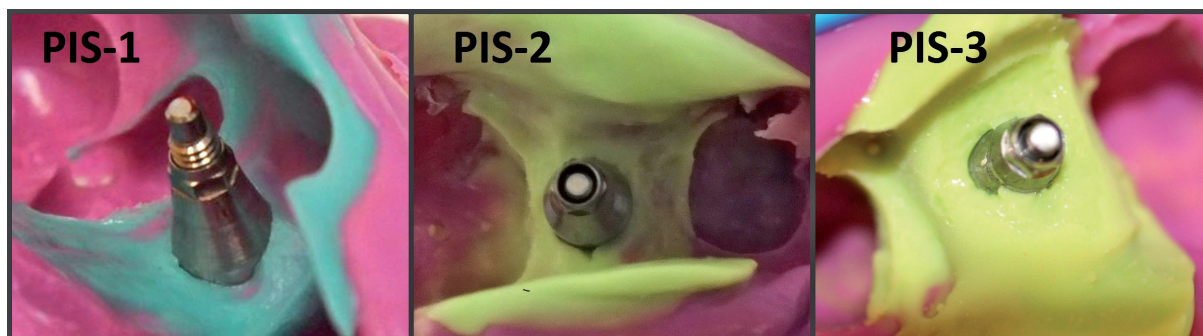


Fig. 1. The authors' prosthetic impression scale (PIS): 1) ideal projection of the soft tissue; 2) satisfactory projection of the soft tissue; 3) inadequate projection of the soft tissue

bubbles, scratches) and 3 is inadequate projection of the soft tissue (cavities, large cracks in the impression material).

The statistical analysis was based on the Mann-Whitney test, and was carried out using STATISTICA 10 software (StatSoft Polska, Kraków, Poland). Values below $p = 0.05$ were considered statistically significant.

Results

In the study, the supracrestal height of periimplant soft tissue (SHPST) was from 2 mm to 5 mm in both groups. The mean value of the soft tissue preparation was 3.72 mm in the laser group and 3.31 mm in the control group.

Painless preparation of the soft tissue was reported in six cases in the laser group. In the control group no painless treatment was reported. No severe pain was reported in the laser group, whereas

in the control group severe pain was experienced by 16 patients. The statistical analysis of the NRS-11 scores revealed significantly lower pain values in the Er:YAG laser group. The mean pain value on the NRS-11 for the Er:YAG and scalpel groups were 2.6 and 6, respectively (Fig. 2)

The study findings show a significant difference in the pain scores on the NRS-11 scale in relation to the SHPST. In the experimental group, the mean pain value during soft tissue preparation was 1.8 (SHPST \leq 3 mm) and 3.3 (SHPST $>$ 3 mm). In the control group, the mean pain values amounted to 4.7 (SHPST \leq 3 mm) and 7.4 (SHPST $>$ 3 mm) (Fig. 3).

The impression of the implant emergence profile, made by the open tray impression method, showed satisfactory quality (PIS-2) of the implant emergence profile projection in 19 cases, and ideal quality (PIS-1) in seven cases. In 4 out of 30 cases, the quality of the impression was found to be inadequate (PIS-3).

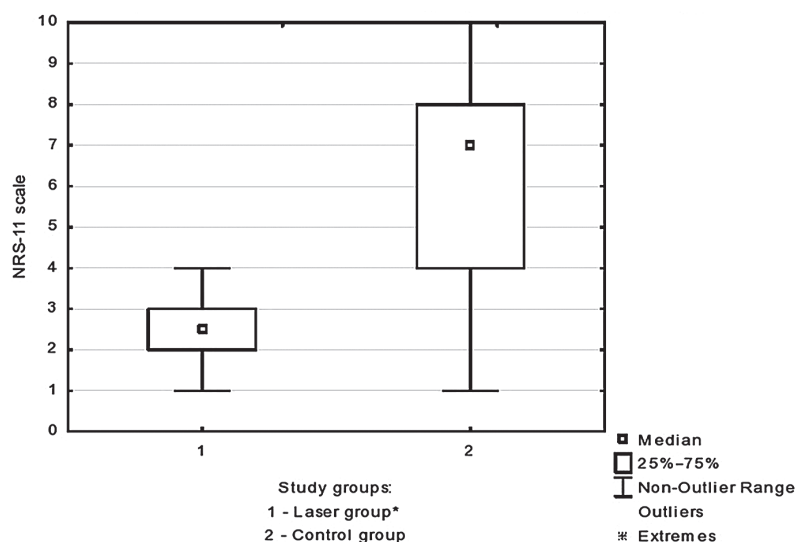


Fig. 2. NRS-11 pain values for the Er:YAG laser group and the scalpel (control) group

* statistically significant difference compared to control group; $p < 0.05$.

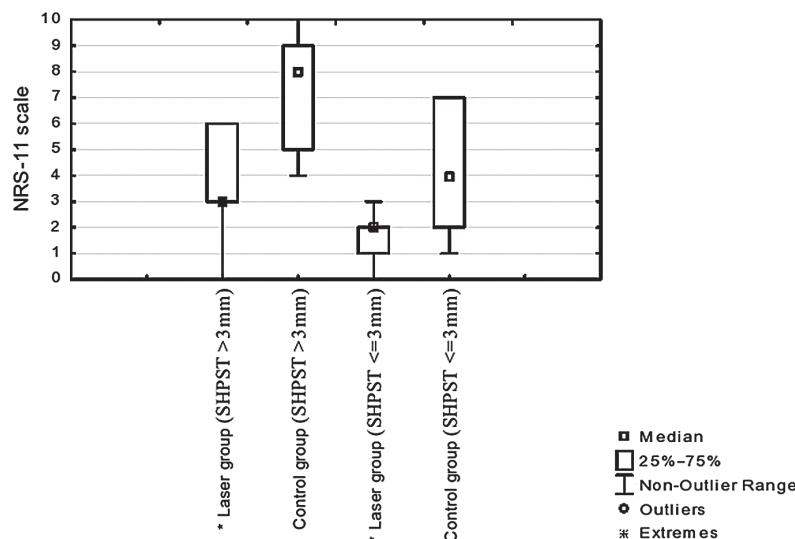


Fig. 3. NRS-11 pain values for the Er:YAG laser group and the scalpel (control) group in relation to the supracrestal height of periimplant soft tissue

* statistically significant difference compared to control group; $p < 0.05$; SHPST – supracrestal height of periimplant soft tissue.

Discussion

Fear of pain and of having an anesthetic administered with a needle is one of the reasons some patients avoid visits to dental surgery facilities. The technology of cutting tissue with lasers considerably reduces pain and even allows minor surgical procedures to be carried out without administering an anesthetic [20].

There are few reports on intraoperative evaluation of perceived pain during the ablation of soft tissue using a laser beam under topical anesthesia [21–23]. Studies describing pain during the removal of soft tissue with an Er:YAG laser without anesthesia are even more scarce.

Chen et al. [21] reported painless ablation of soft tissue using an Er:YAG laser and topical application of 20% benzocaine. A study by Fornaini et al. [22] showed good pain control results during operations performed only with topical anesthetics as shown in VAS tests. In the present study no pain was reported in six cases, mild pain in 18 cases, and moderate pain in 6 cases out of 30 procedures conducted using an Er:YAG laser without anesthesia.

In their comparative analysis of subjective tolerance and acceptance of therapy in children needing soft tissue treatments, Genovese et al. [24] showed a good rate (63%) of acceptance and tolerance of soft tissue surgery performed using Er,Cr:YSGG and Er:YAG lasers. In the present study a pain score ≤ 3 in NRS-11 scale was observed in 24 cases out of 30 procedures (80%) performed without anesthesia. Chen et al. [21] and Berger et al. [25] recommended that to minimize pain when using Er,Cr:YSGG and Er:YAG lasers for soft tissue preparation, the maximum energy output should not exceed 150 mJ and the frequency should not be lower than 30 Hz.

The laser settings used in the present study (300 mJ, 18 Hz) differ from those recommended by other authors. The reason for using the Er:YAG laser settings applied in the present study was that in the authors' opinion compensating for lower laser energy with higher impulse frequency is not the best solution: It intensifies the thermal effect because there is less time for tissue cooling. Therefore, increased laser power at a lower frequency ensures a better effect. On the other hand, lower power is recommended for precise cutting in the case of continuous-wave lasers, i.e. CO₂ lasers.

An Er:YAG laser without an optical fiber and with a rectangular energy distribution profile (a flat-top beam) was used in this study. These lasers generate high power, a uniform beam and have low energy loss during transport. In most lasers presently in use, the energy beam is transport-

ed to the tip by means of an optical fiber, which distorts the energy distribution. In that type of laser, the highest energy is in the middle of the beam, with much lower energy at the edges. Concentrating the beam power in the very center with relatively low power and high frequency settings may cause thermal damage in the tissue. In Er:YAG lasers without optical fibers the beam energy is sent directly, with uniform distribution from the handle to the tip. Rectangular energy distribution allows for even tissue ablation and does not cause tissue burns, even at an energy output of 300 mJ. In addition, a relatively low frequency in combination with a cooling factor prevents excessive increases in temperature. It is important to use circular movements when treating the tissue, with no static irradiation of only one area. This reduces pain and photoablates the tissue without burning it.

Grandi et al. [26] suggested that non-removal of abutments placed during surgery results in a statistically significant reduction of the crestal bone resorption around immediately restored implants. Koutouzis et al. [27] showed that disconnection and reconnection of the abutment, performed twice, causes minimal marginal bone loss. The Er:YAG laser used in the present study and its ablation characteristics are useful for preparing an accurate implant emergence profile. This procedure reduces the number of abutment disconnections and reconnections.

Laser ablation combined with reduced tissue contraction allows for precise modeling of the gum line, easy correction of gingival hypertrophy and accurate uncovering of the implant. All of the above reduce the duration of prosthetic treatment after the implantation. Studies indicate that the laser activity on the implant surface neither damages its structure nor excessively increases its temperature [28].

Uniform ablation of the tissue ensures faster healing than in the case of a scalpel. It also prevents scarring and causes minimal (if any) post-surgery swelling [3, 29]. Moreover, laser ablation permits the soft tissue to be removed one layer at a time and prepared accurately, and allows the emergence profile to be modeled similarly as in the case of healing screws. Thanks to the laser, impression can be taken from the transfer level directly after the uncovering of the implant, thus reducing the treatment time.

Further studies should be conducted to assess wound healing using different laser wavelengths.

The authors concluded that minor soft tissue surgery using Er:YAG lasers considerably reduces pain and even permits such procedures to be performed without any anesthetic.

Additionally, in most cases the quality of the impression is accurate enough to prepare a prosthetic reconstruction immediately at the time of

second stage surgery. Furthermore, the use of a laser reduces the time and cost of treatment.

References

- [1] **Wigdor H, Walsh J, Featherstone JDB, Visuri SR, Fried D, Waldvogel JL:** Lasers in dentistry. *Lasers Surg Med* 1995, 16, 103–133.
- [2] **Bader H:** Use of lasers in periodontics. *Dent Clin North Am* 2000, 44, 779–792.
- [3] **Ishikawa I, Aoki A, Takasaki AA:** Potential applications of Erbium:YAG laser in periodontics. *J Periodontol Res* 2004, 4, 275–285.
- [4] **Schuller DE:** Use of the laser in the oral cavity. *Otolaryngol Clin North Am* 1990, 23, 31–42.
- [5] **Mello I, Robazza CR, Antoniazzi JH:** Influence of Er:YAG laser irradiation on apical sealing of four different sealers. *Braz Dent J* 2004, 3, 190–193.
- [6] **Dostalova T, Jelinkova H, Krejsa O, Hamal H:** Evaluation of the surface changes in enamel and dentin due to possibility of thermal overheating induced by Erbium:YAG laser radiation. *Scanning Microsc* 1996, 10, 285–290.
- [7] **Glenn VA:** Erbium lasers in dentistry. *Dent Clin N Am* 2004, 48, 1017–1059.
- [8] **Crespi R, Barone A, Covani U:** Er:YAG laser scaling of diseased root surfaces: A histologic study. *J Periodontol* 2006, 77, 218–222.
- [9] **Eberhard J, Ehlers H, Falk W, Acil Y, Albers HK, Jepsen S:** Efficacy of subgingival calculus removal with Er:YAG laser compared to mechanical debridement: An *in situ* study. *J Clin Periodontol* 2003, 30, 511–518.
- [10] **Gaspirc B, Skaleric U:** Clinical evaluation of periodontal surgical treatment with an Er:YAG Laser: 5-year results. *J Periodontol* 2007, 78, 1864–1871.
- [11] **Tomasi C, Schander K, Dahlen G, Wennstrom JL:** Short-term clinical and microbiologic effects of pocket debridement with an Er:YAG laser during periodontal maintenance. *J Periodontol* 2006, 77, 111–118.
- [12] **Bednarz W:** The thickness of periodontal soft tissue ultrasonic examination – current possibilities and perspectives. *Dent Med Probl* 2011, 48, 3, 303–310.
- [13] **Hoelscher DC, Simons AM:** The rationale for soft-tissue grafting and vestibuloplasty in association with endosseous implants: A literature review. *J Oral Implantol* 1994, 20, 282–291.
- [14] **Kan JYK, Rungcharassaeng K, Lozada JL, Zimmerman G:** Facial gingival tissue stability following immediate placement and provisionalization of maxillary anterior single implants: A 2- to 8-year follow-up. *Int J Oral and Max Impl* 2011, 26, 179–187.
- [15] **Hsu YT, Shieh CH, Wang HL:** Using soft tissue graft to prevent mid-facial mucosal recession following immediate implant placement. *J Int Acad Periodontol* 2012, 14, 76–82.
- [16] **Cosyn J, Hooghe N, de Bruyn H:** A systematic review on the frequency of advanced recession following single immediate implant treatment. *J Clin Periodontol* 2012, 39, 582–589.
- [17] **Santos Calderon P, Peixoto RF, Gomes VM, da Mota Corrêa AS, de Alencar EN, Rossetti LM, Conti PC:** Concordance among different pain scales in patients with dental pain. *J Orofac Pain* 2012, 26, 126–131.
- [18] **Jensen MP, Karoly P, O’Riordan EF, Bland F, Burns RS:** The subjective experience of acute pain. An assessment of the utility of 10 indices. *Clin J Pain* 1989, 2, 153–159.
- [19] **Williamson A, Hoggart B:** Pain: A review of three commonly used pain rating scales. *J Clin Nurs* 2005, 14, 798–804.
- [20] **Renvert S, Lessem J, Dahle n G, Lindahl C, Svensson M:** Topical minocycline micro-spheres versus topical chlorhexidine gel as an adjunct to mechanical debridement of incipient peri-implant infections: A randomized clinical trial. *J Clin Periodontol* 2006, 33, 362–369.
- [21] **Chen CK, Chang NJ, Ke JH, Fu E, Lan WH:** Er:YAG laser application for removal of keratosis using topical anesthesia. *J Dent Sci* 2013, 8, 196–199.
- [22] **Fornaini C, Rocca JP, Merigo E, Meleti M, Manfredi M, Nammour S, Vescovi P:** Low energy KTP laser in oral soft tissue surgery: A 52 patients clinical study. *Med Oral Patol Oral Cir Bucal* 2012, 17, 287–291.
- [23] **Trajtenberg C, Adibi S:** Removal of an irritation fibroma using an Er,Cr:YSGG laser: A case report. *Gen Dent* 2008, 56, 648–651.
- [24] **Genovese MD, Olivi G:** Laser in paediatric dentistry: Patient acceptance of hard and soft tissue therapy. *Eur J Paediatr Dent* 2008, 9, 13–17.
- [25] **Berger JW, Amico DJ:** Modeling of erbium: YAG laser-mediated explosive photovaporization: Implications for vitreoretinal surgery. *Ophthalmic Surg Lasers* 1997, 28, 133–139.
- [26] **Grandi T, Guazzi P, Samarani R, Garuti G:** Immediate positioning of definitive abutments versus repeated abutment replacements in immediately loaded implants: Effects on bone healing at the 1-year follow-up of a multicentre randomised controlled trial. *Eur J Oral Implantol* 2012, 5, 9–16.
- [27] **Koutouzis T, Koutouzis G, Gadalla H, Neiva R:** The effect of healing abutment reconnection and disconnection on soft and hard peri-implant tissues: A short-term randomized controlled clinical trial. *Int J Oral Max Impl* 2013, 28, 807–814.
- [28] **Quirynen M, Vogels R, Peeters W, van Steen-berghe D, Naert I, Haffajee A:** Dynamics of initial subgingival colonization of ‘pristine’ peri-implant pockets. *Clin Oral Impl Res* 2006, 17, 25–37.
- [29] **Gabrić Pandurić D, Sušić M, Brozović J, Smojver I, Vučićević V, Katanec D:** Diode and Er:YAG laser vs. conventional technique for second stage surgery. *Clin Oral Impl Res* 2014, 25, 397.

Address for correspondence:

Jacek Matys
Private Dental Practice
Lipowa 18
Wschowa
Poland
Tel.: +48 79 151 1789
E-mail: jacek.matys@wp.pl

Conflict of interest: None declared

Received: 11.07.2015

Revised: 15.02.2016

Accepted: 31.03.2016